



# Equine Phobia Field Cases

Updated  
February 2023



## PHOVIA CASE 1

# “Conundrum”

- 5 year old, AQHA Paint Stallion
  - Owned by DVM

### Healthy Stallion in training

Pythiosis scar-lesion on medial right cannon structure

Self inflicted traumatic tissue damage from collecting semen on a phantom



## “Conundrum”

- **Diagnosis**

- Traumatic wound abrasions of medial carpus area, both front legs and right caudal pastern trauma

- **Treatments**

- Prior to first treatment leg rinsed with saline and chlorhexidine
- Two Phovia treatments per session , 7 days apart
- Derma-gel hydrogel applied daily for first week, and every other day after second Phovia session



## PHOVIA CASE 1

# “Conundrum”

- Phovia treatments- April 11th and 18th
  - April 11<sup>th</sup>, two Phovia , 2-minute treatments, back-to-back on medial right carpus
  - Left medial carpus, one Phovia , 2-minute treatment
  - Subsequent daily hydrogel application.
  - April 18<sup>th</sup>, repeat of Phovia protocol above








PHOVIA CASE 1

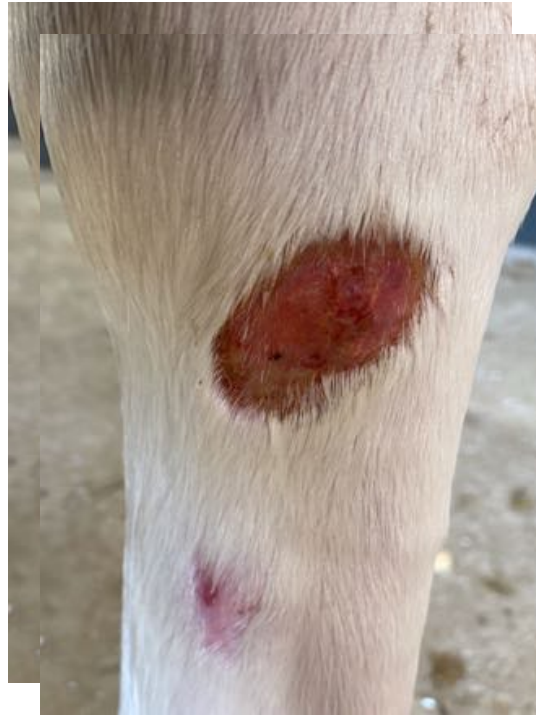## “Conundrum”



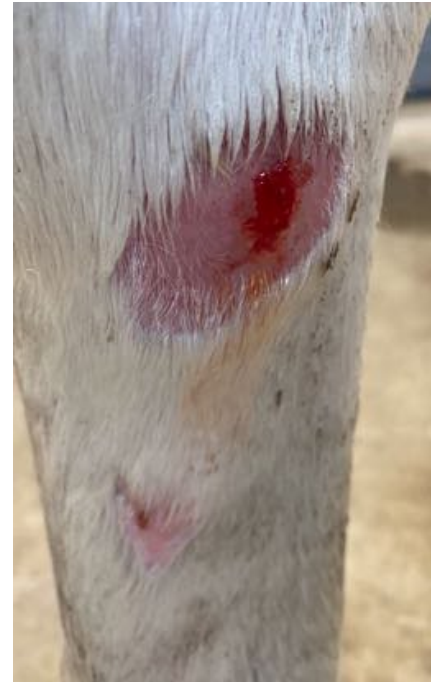

## PHOVIA CASE 1

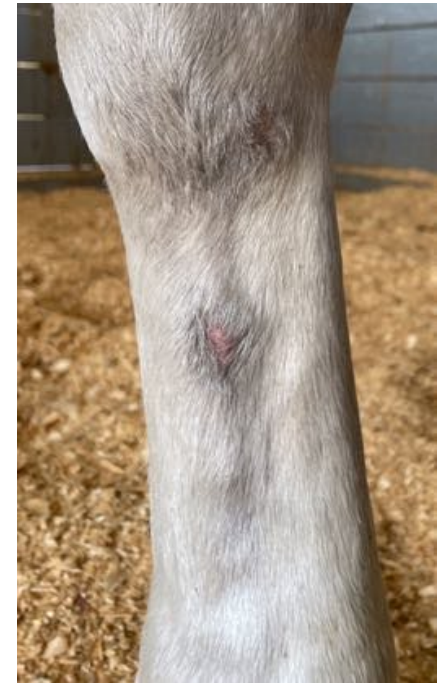# “Conundrum”



April 11



April 18



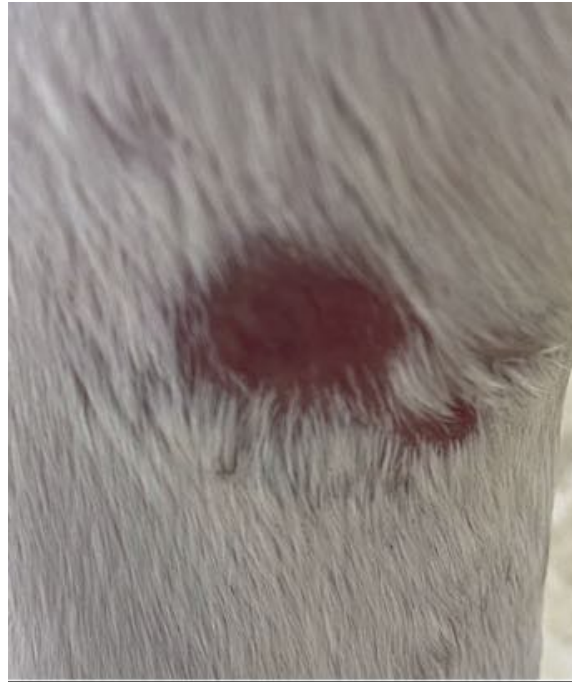May 12



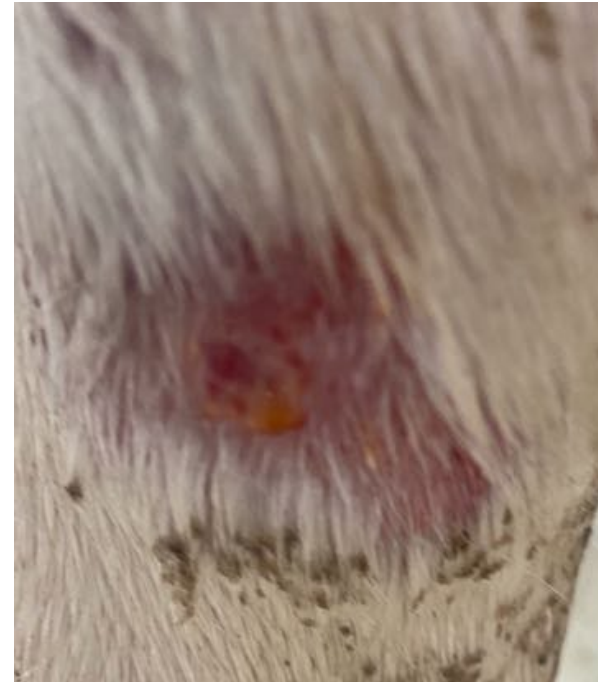

PHOVIA CASE 1

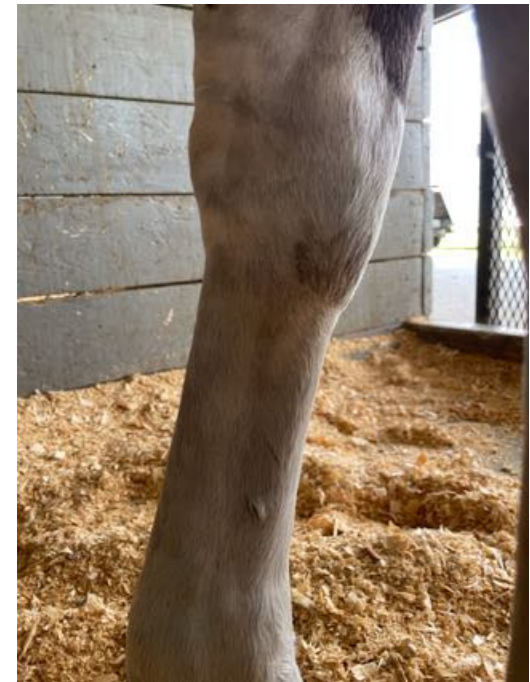## “Conundrum”



April 11th



April 18th





## PHOVIA CASE 1

### Conundrum

- April 18<sup>th</sup> Pythiosis scar not affected by treatment as lesion not active.  
May 12<sup>th</sup> visible, but not inflamed

### Summary

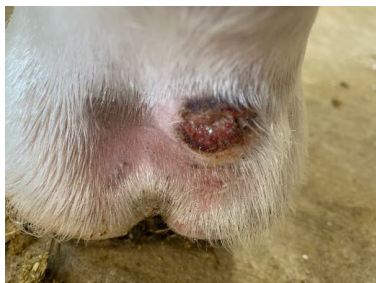Traumatically induced wounds had significant reduction in inflammation and healing time following Phovia application



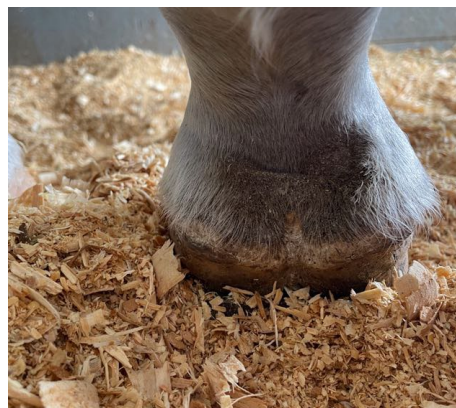## PHOVIA CASE 1

# “Conundrum”

- April 11th



May 12th





## PHOVIA CASE 2

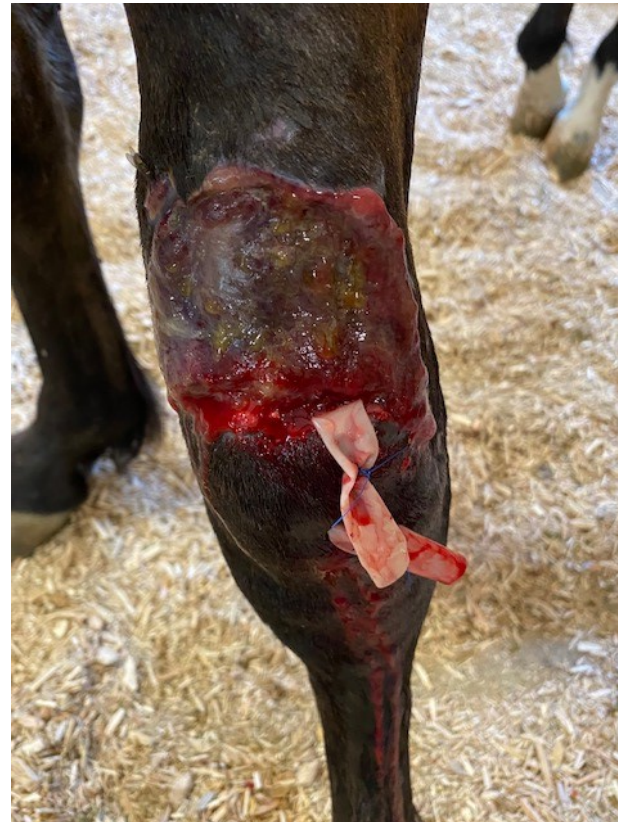### Olive

- One year old Arabian Cross
- Laceration over dorsal left radius
- Initial treatment with PRP 3 days prior
- June 13<sup>th</sup> first Phovia treatment
- Treated with Phovia once per week until August 22nd



## PHOVIA CASE 2

infected wound



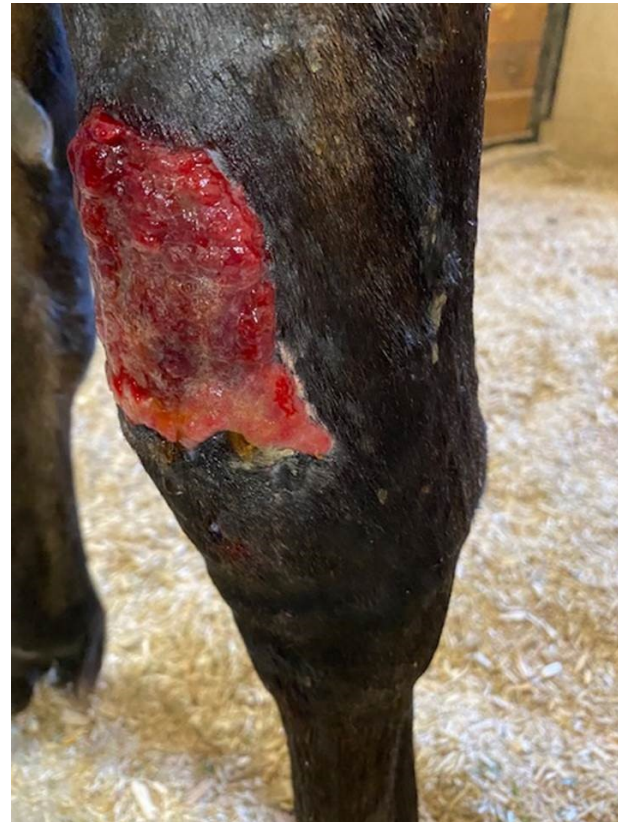First treatment  
June 13th





PHOVIA CASE 2

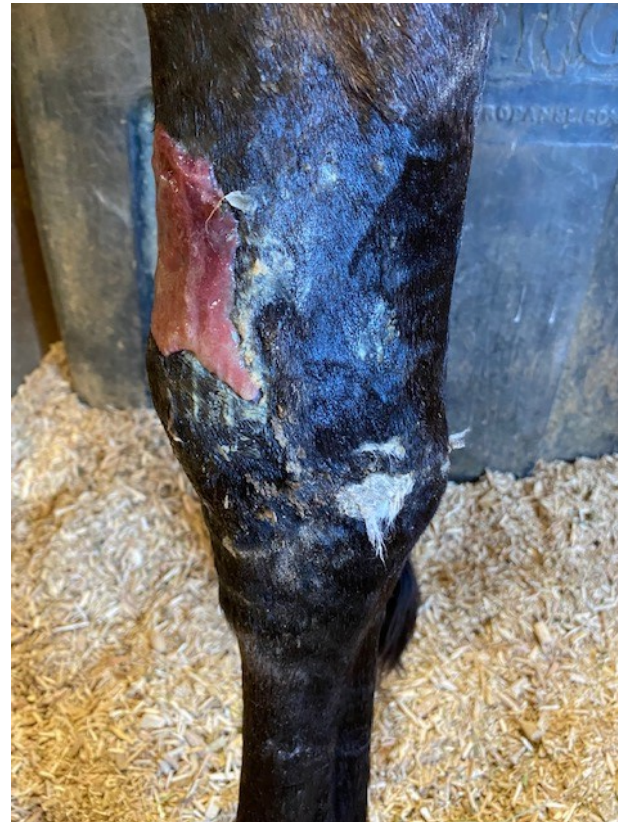## Second Phovia Treatment day



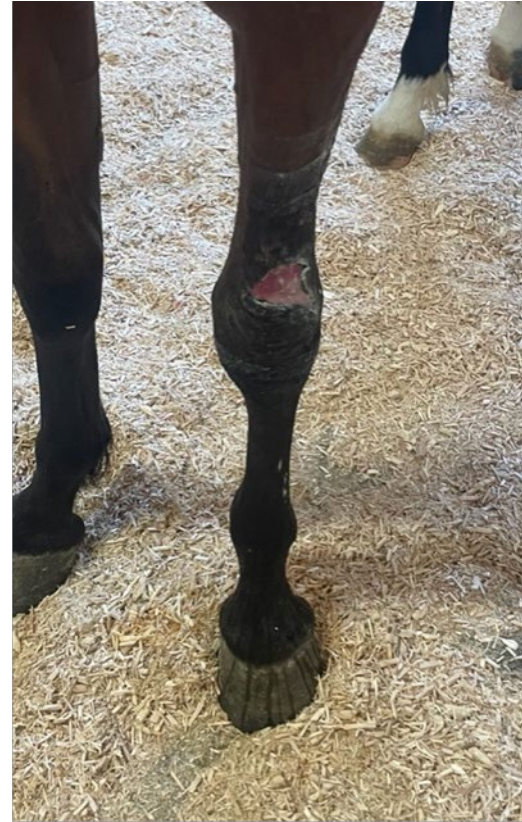2<sup>nd</sup> Treatment  
June 20th



## PHOVIA CASE 2

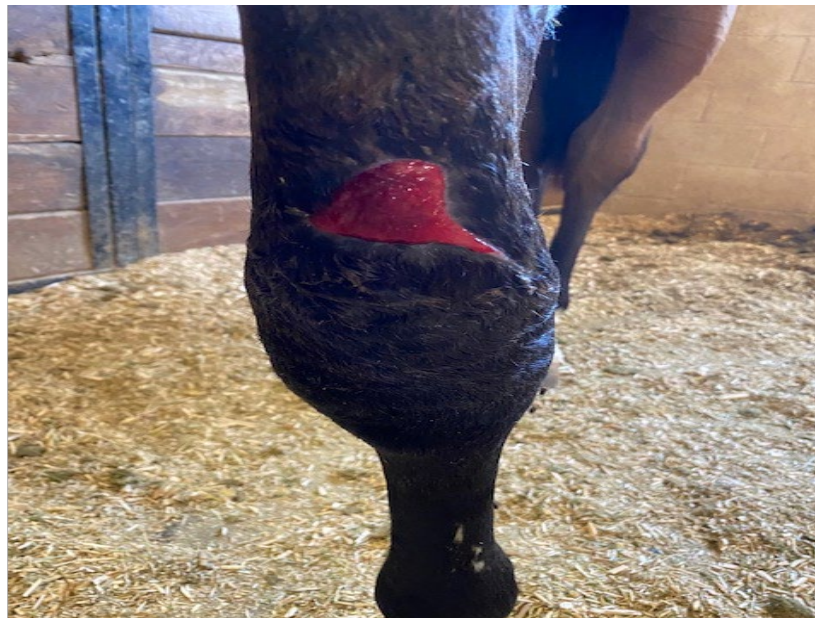

June 22nd

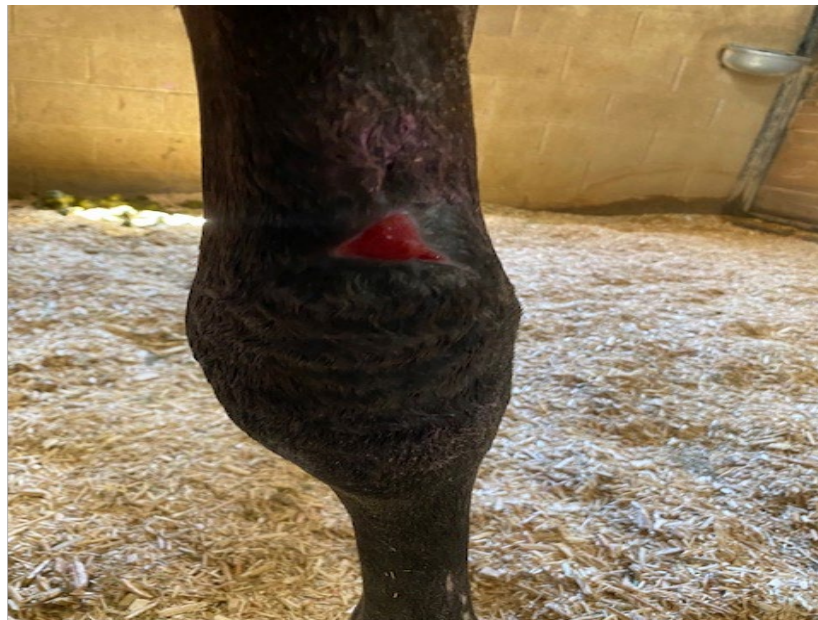

August 1st





August 11th



August 22nd



## PHOVIA CASE 3

### EKO

20 yr. old Thoroughbred gelding,

Chronic wound from September 2021

Weekly bandage changes

Feb 2022 previously closed wound was re-opened

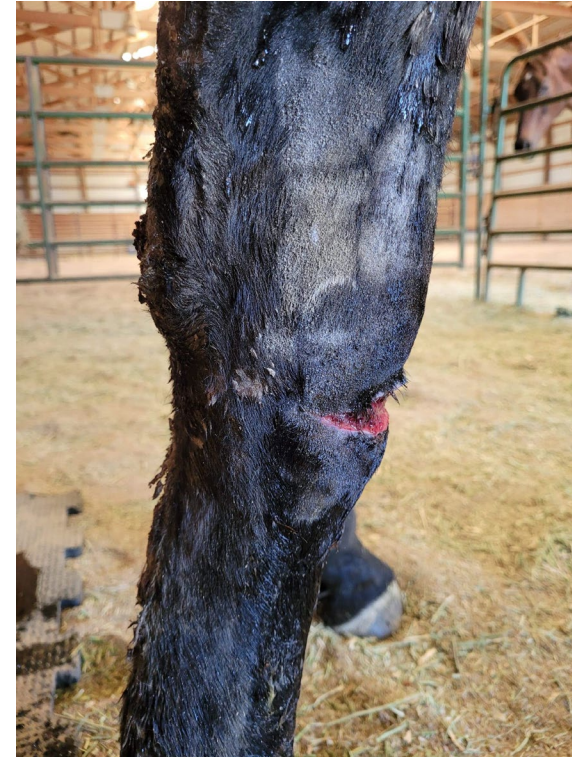



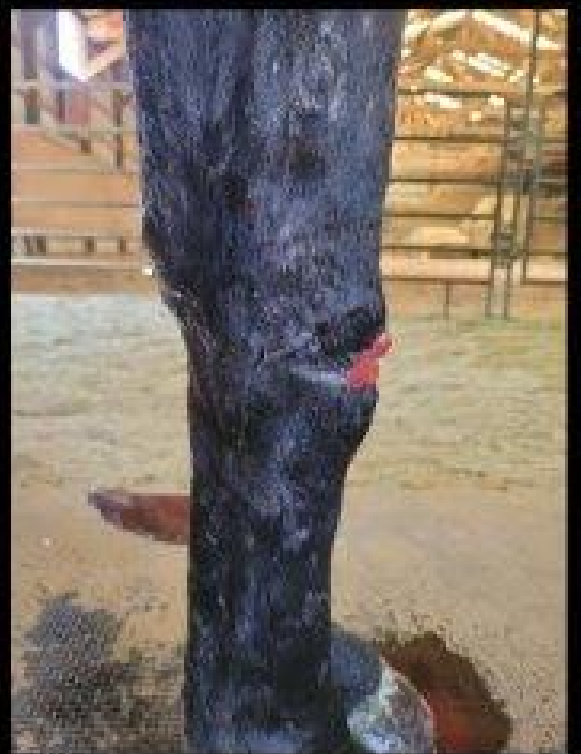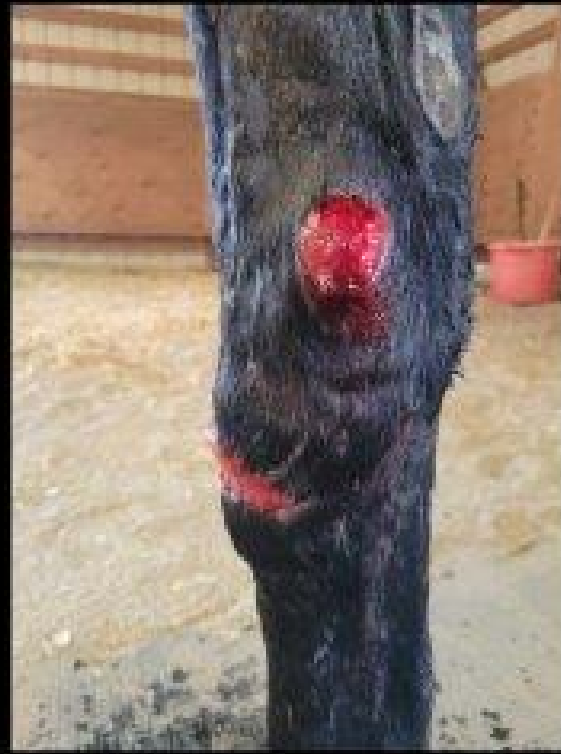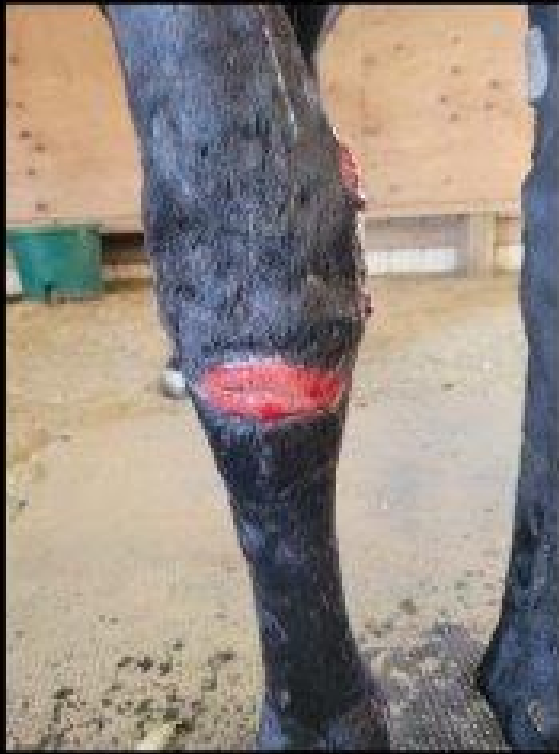## PHOVIA CASE 3

# Treatment

- Phovia treatment once per week (back-to-back) for 6 treatments starting June 17th



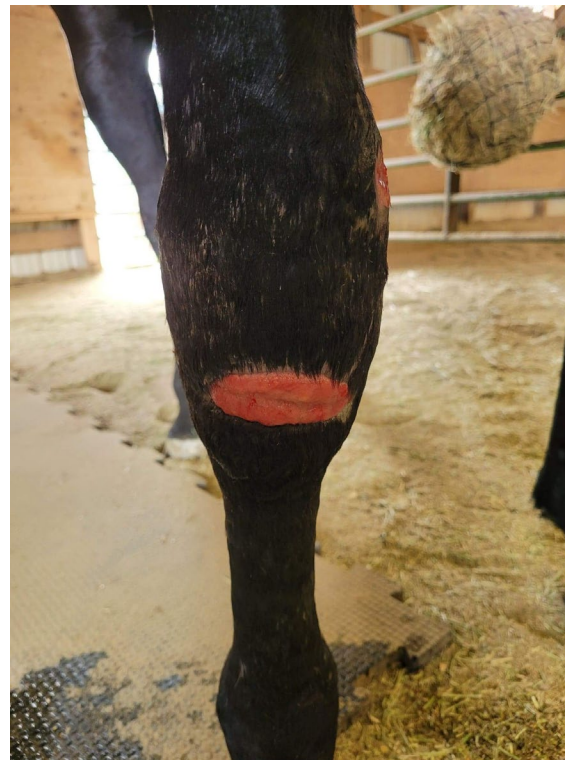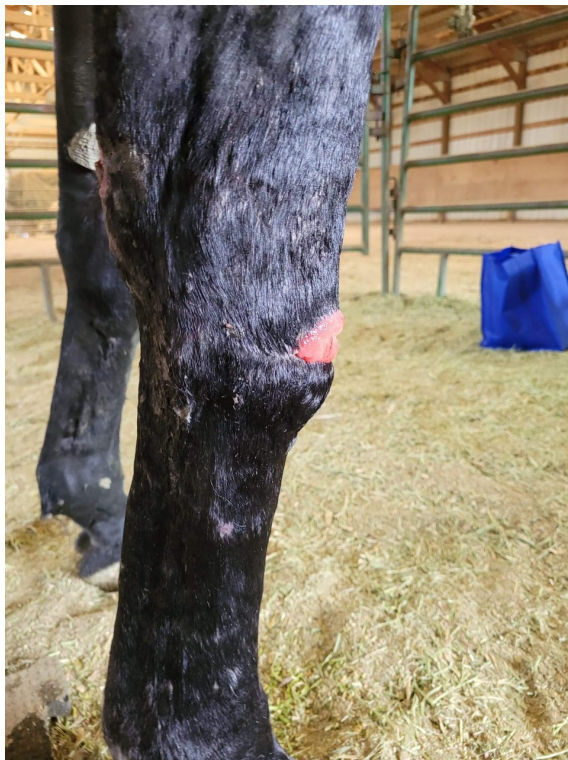6/12 (“Initial”)



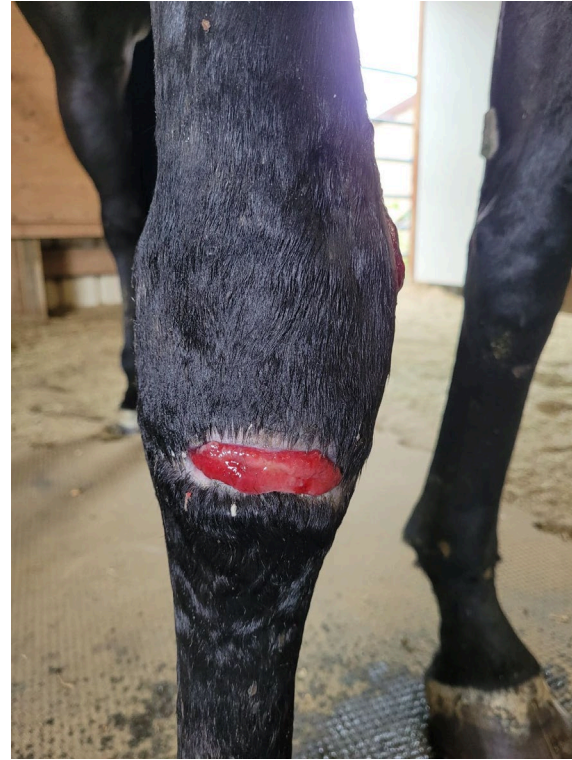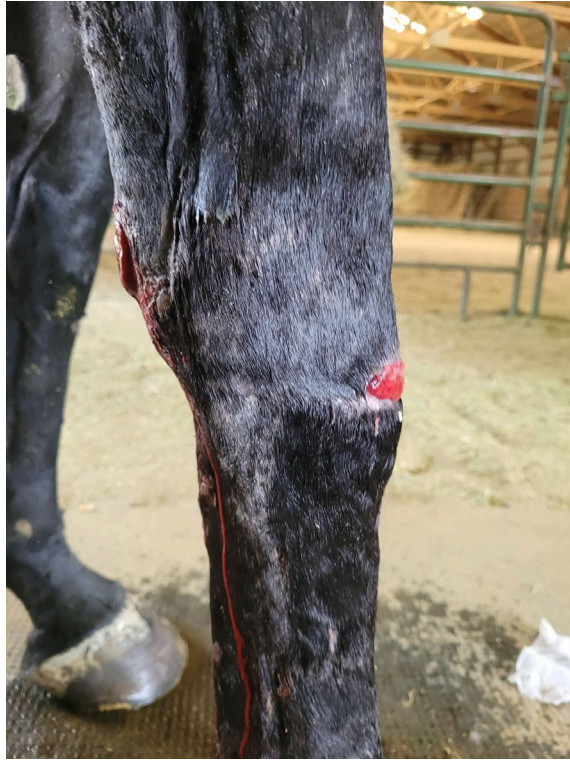6/17

---



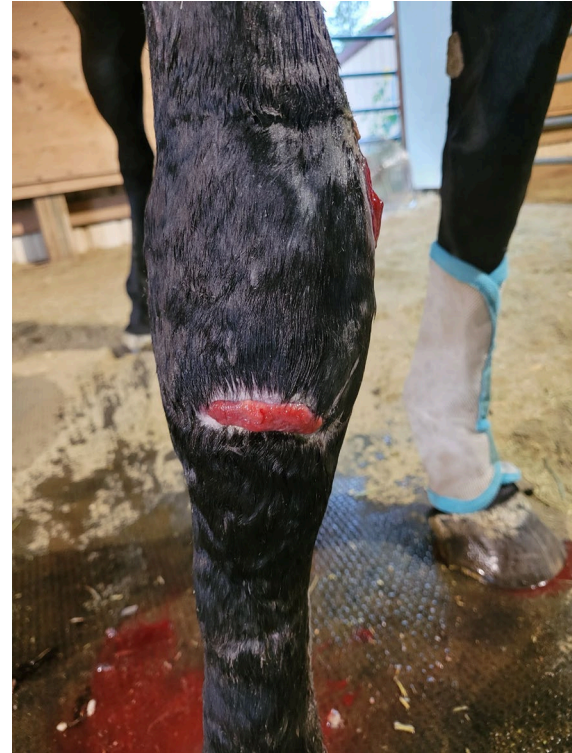

6/22



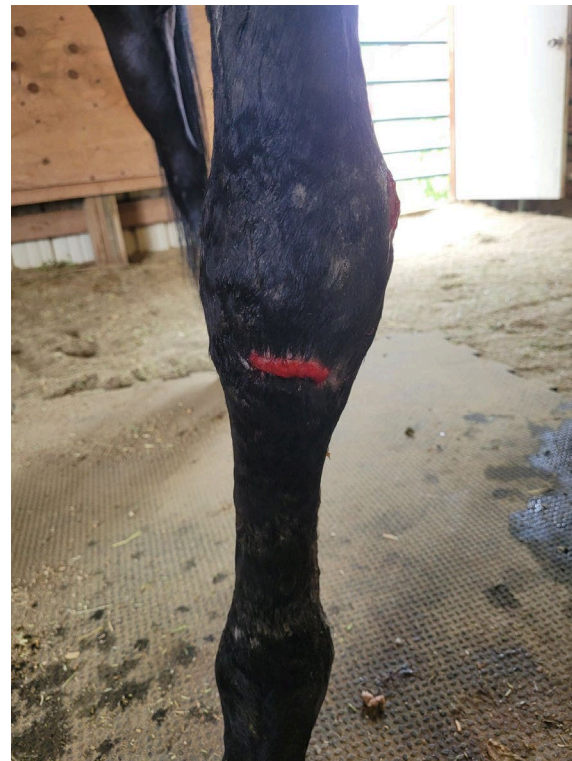7/1



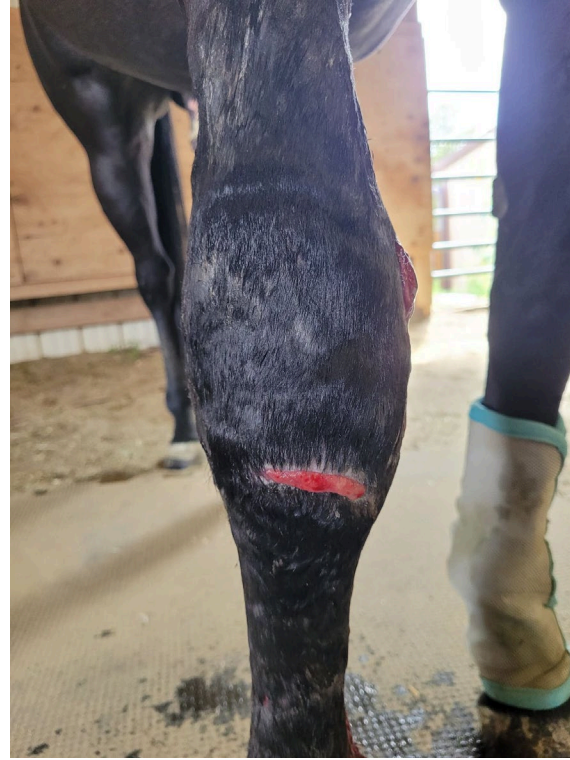

7/6





7/11



7/15



8 yr old event  
Horses





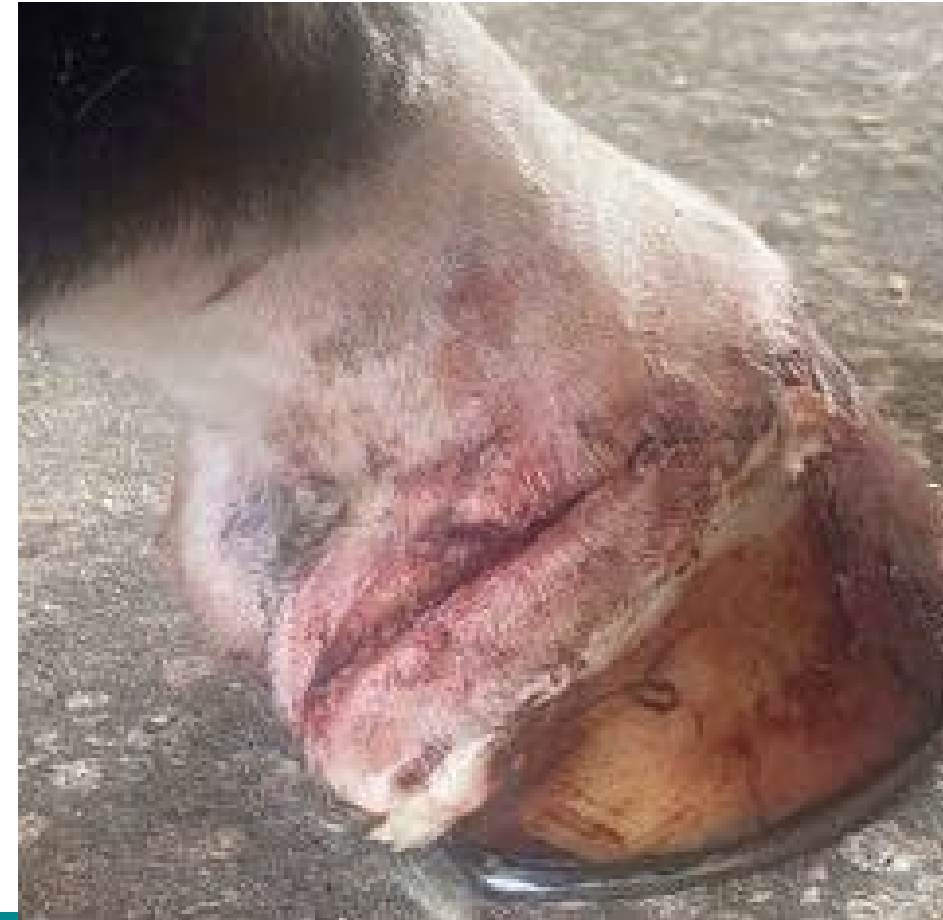## PHOVIA CASE 4

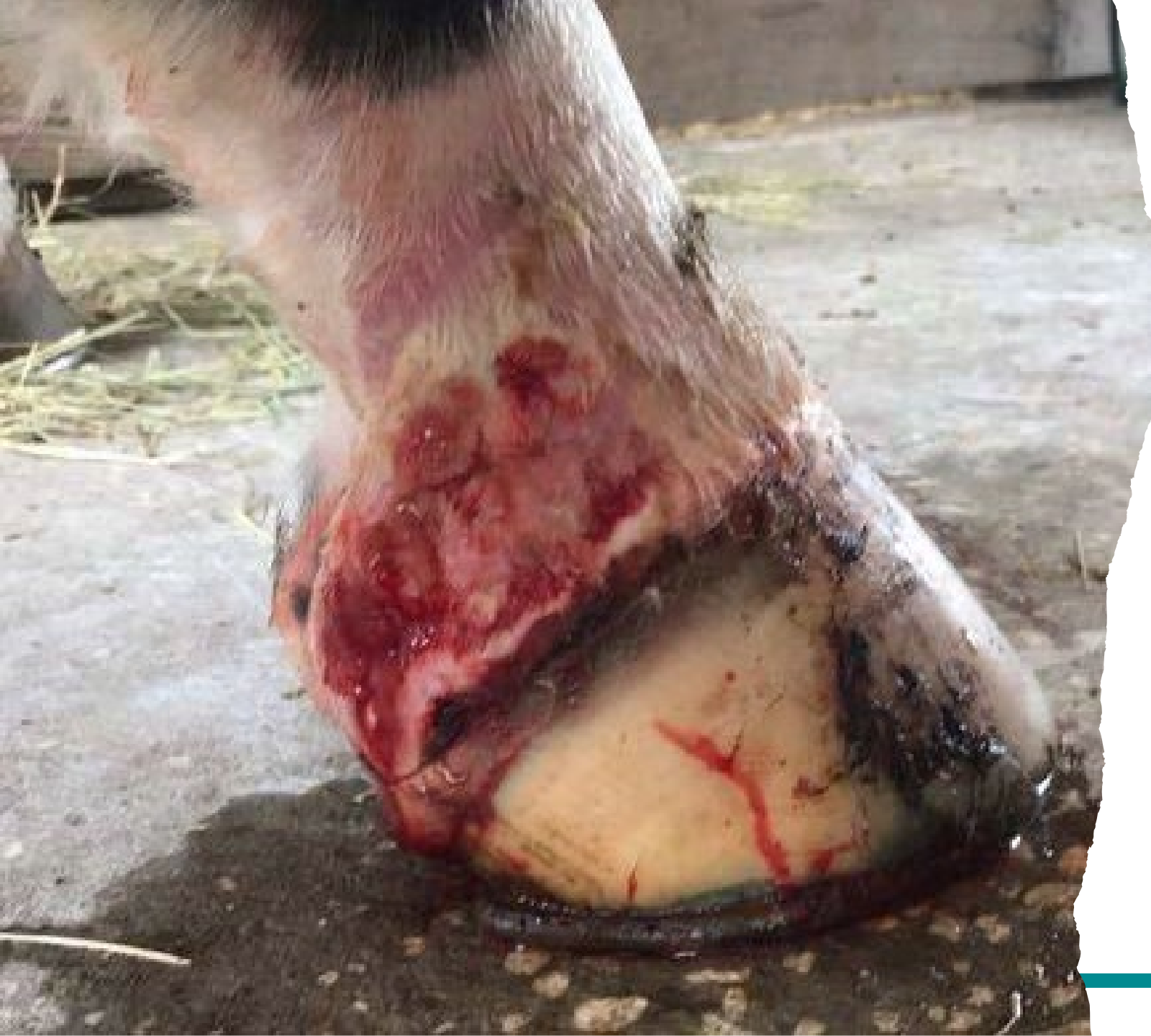### History

Trailer accident  
Arterial laceration

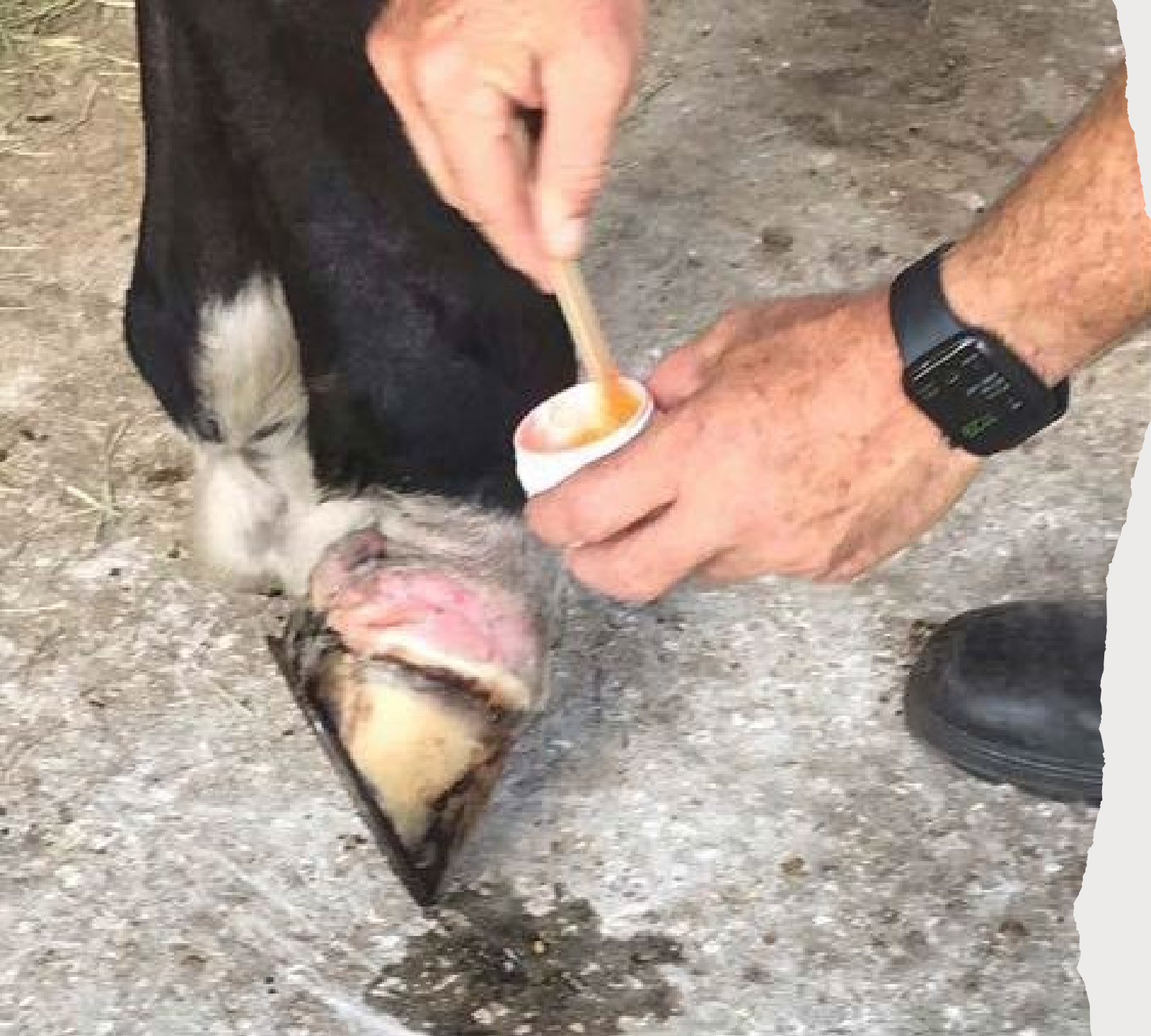Initial Treatments  
were stables

Butazolidin, banamine  
triple antibiotic and  
Wrapped





Pre-Treatment  
April 21<sup>st</sup>

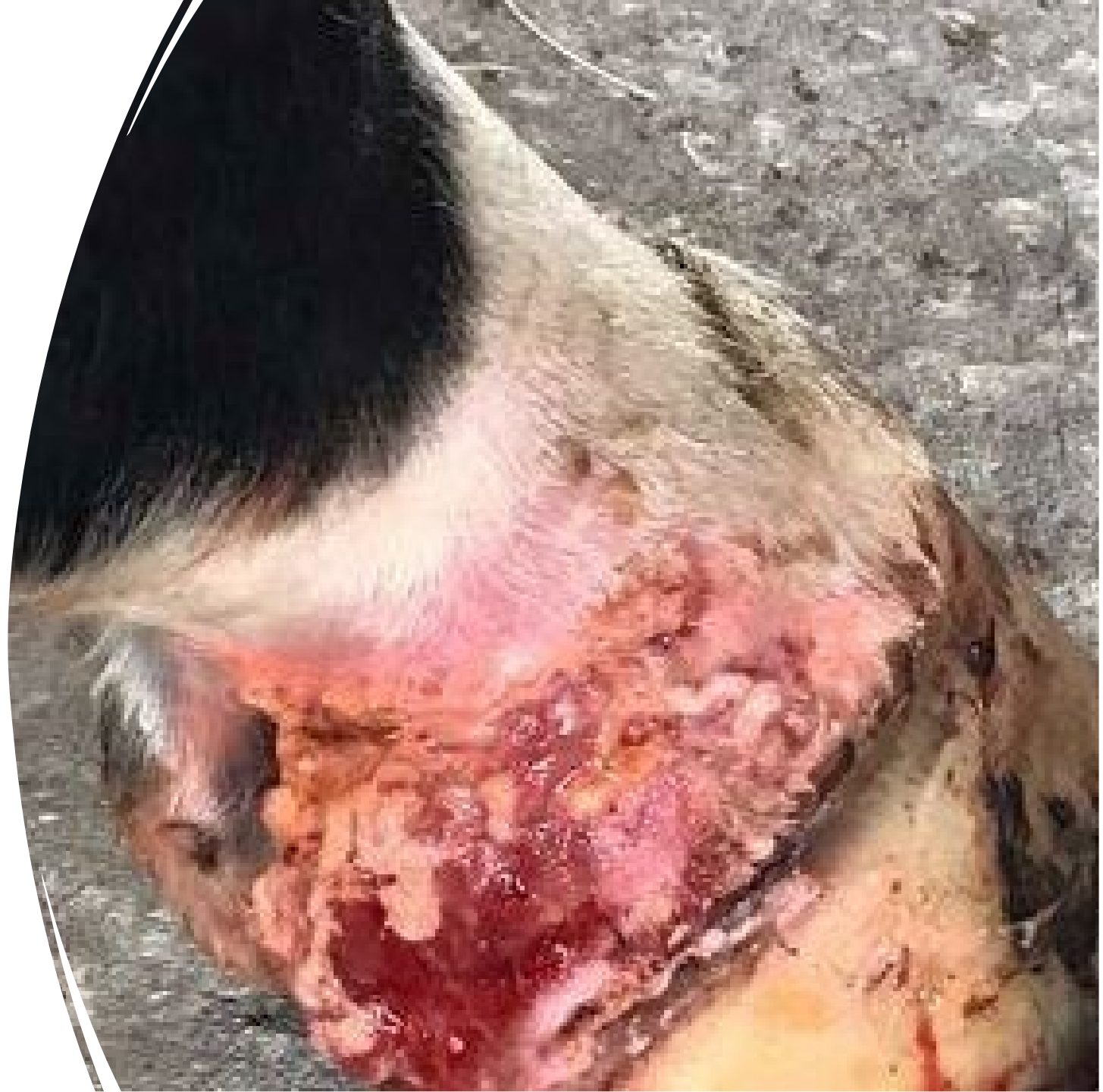


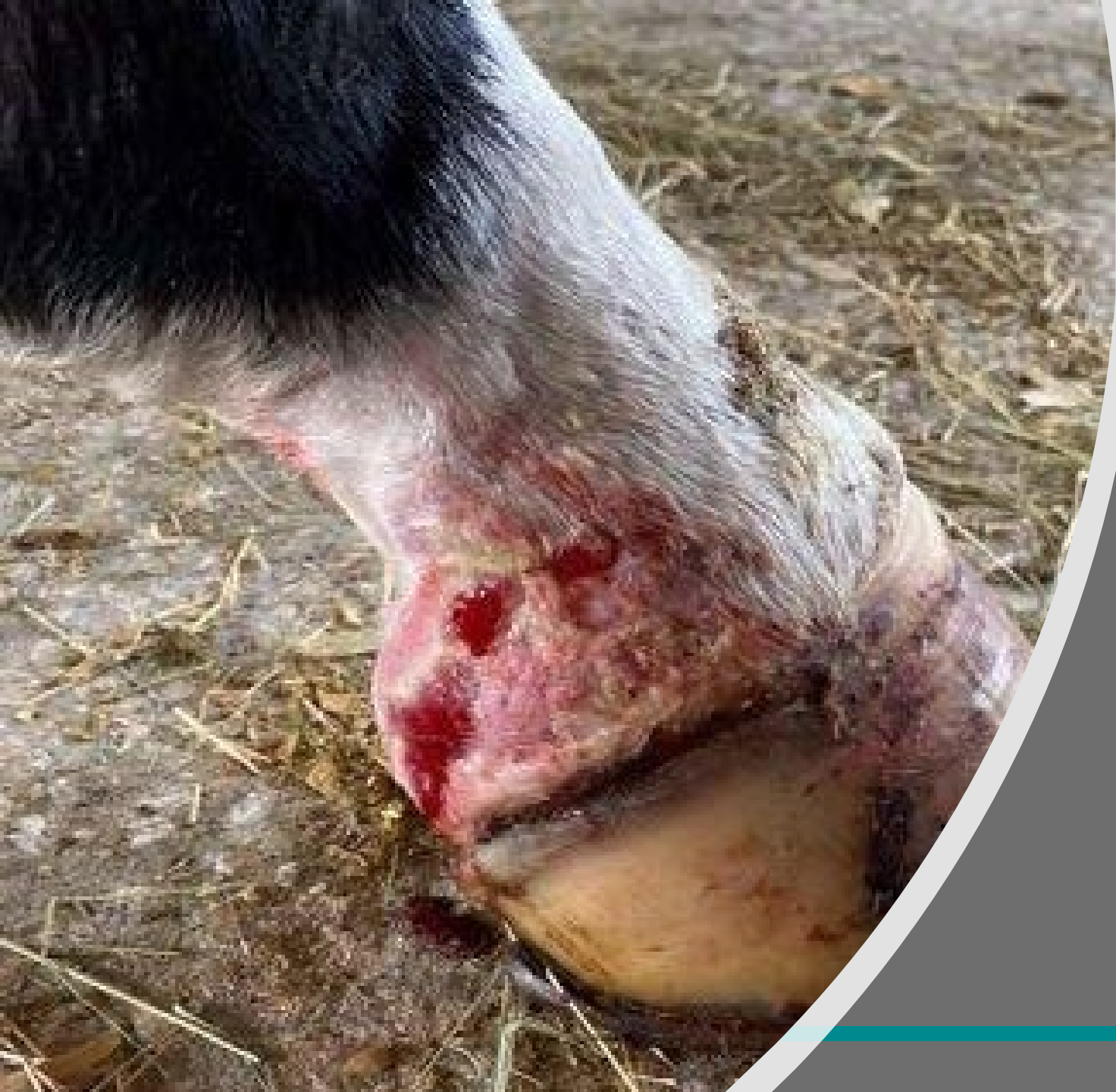


Two treatments  
April 21<sup>st</sup>  
back- to- back

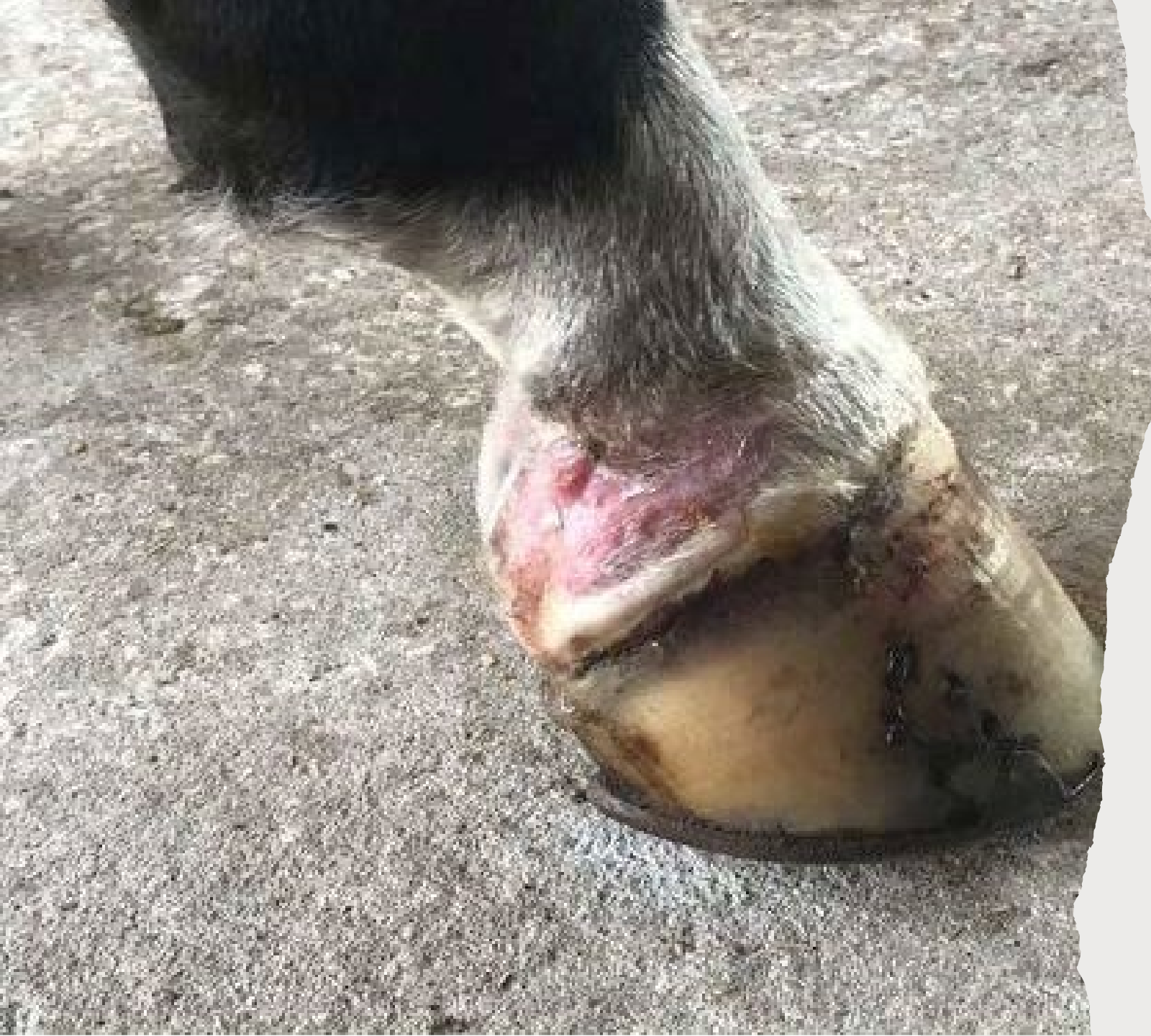- 
- APRIL 21<sup>ST</sup>
  - POST-TREATMENT



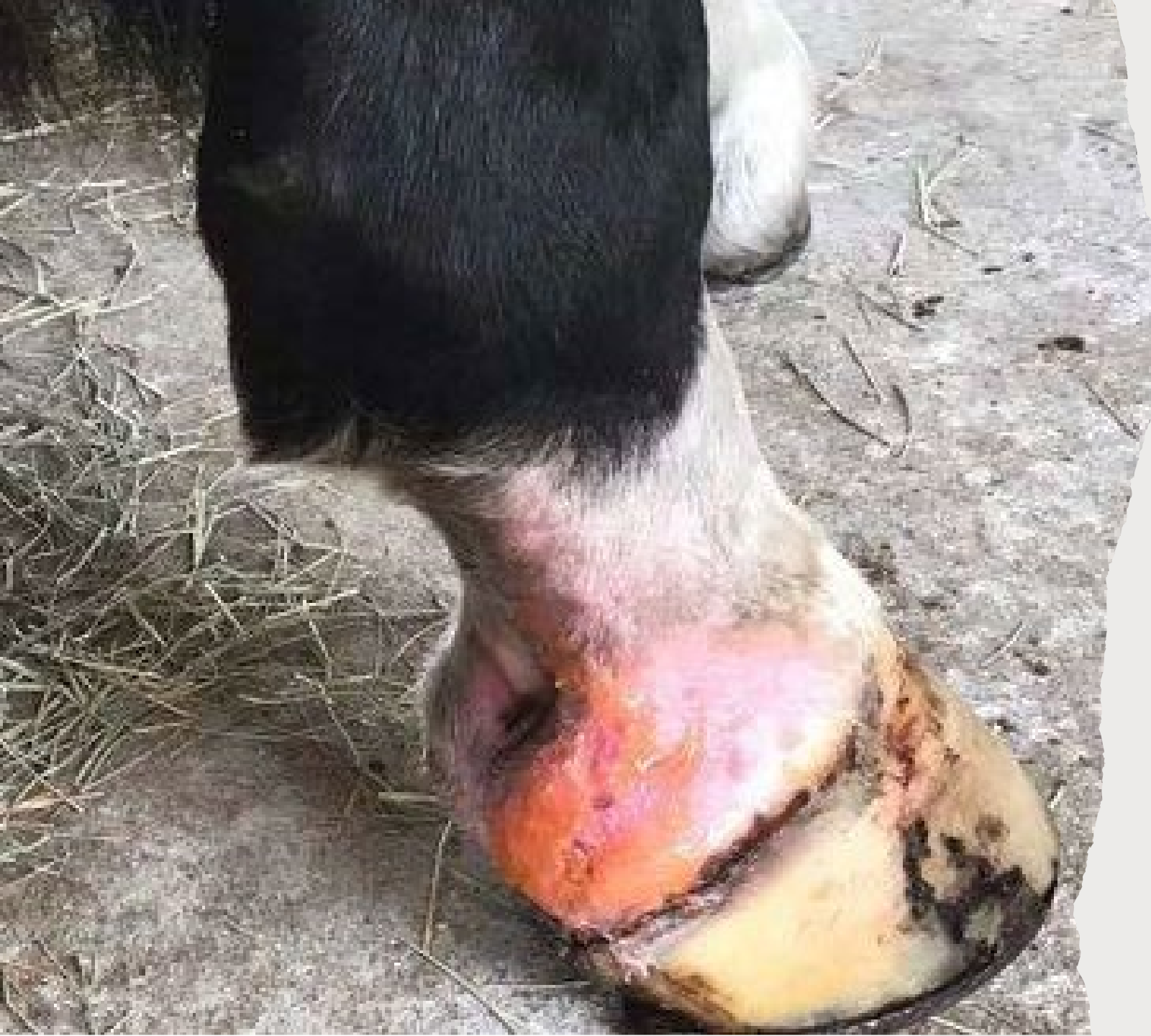

April 25<sup>th</sup> , four days post  
treatment  
“Epithelialization was  
impressive” Chris Newton  
DVM

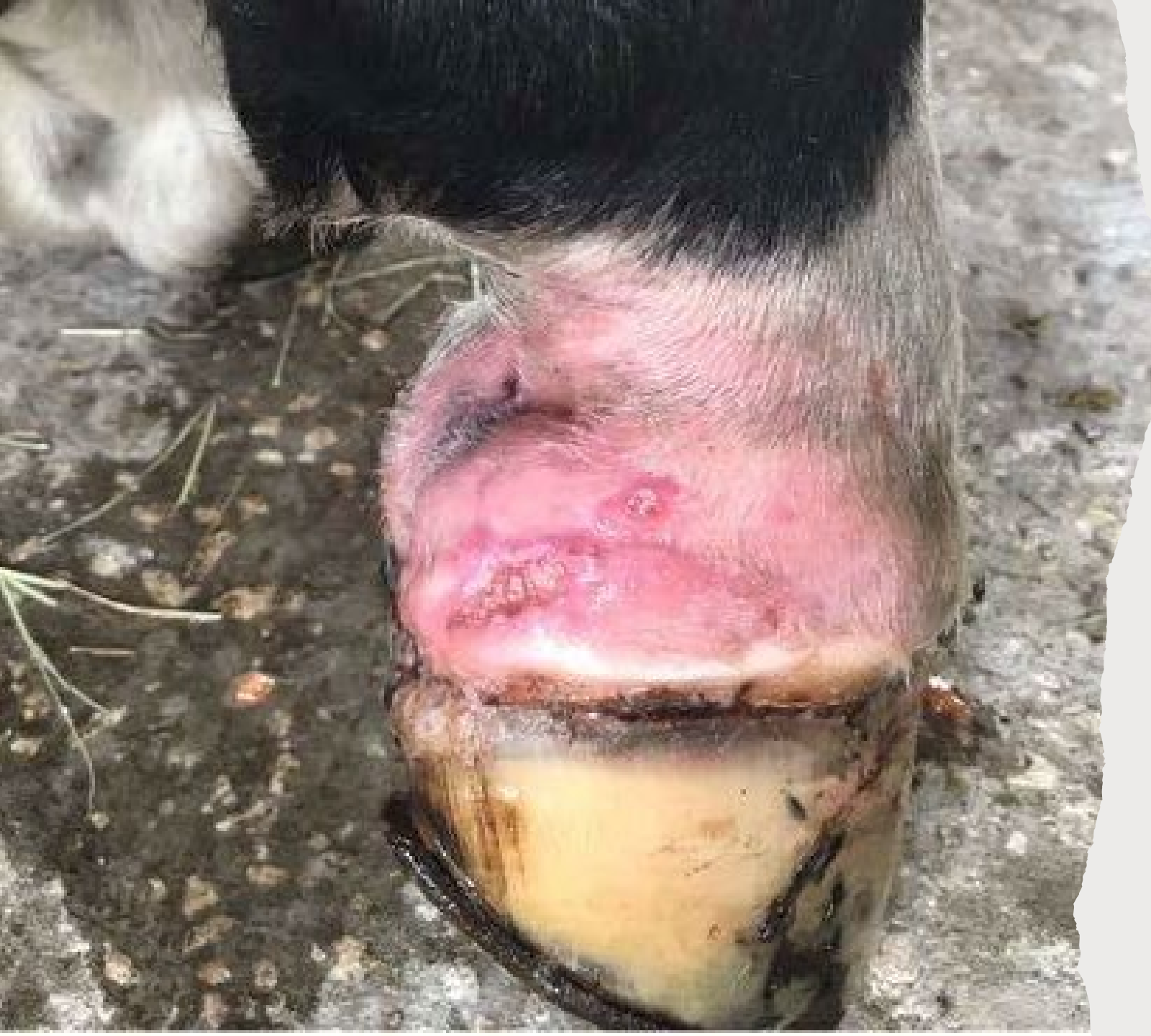



May 4<sup>th</sup> Pre-  
treatment

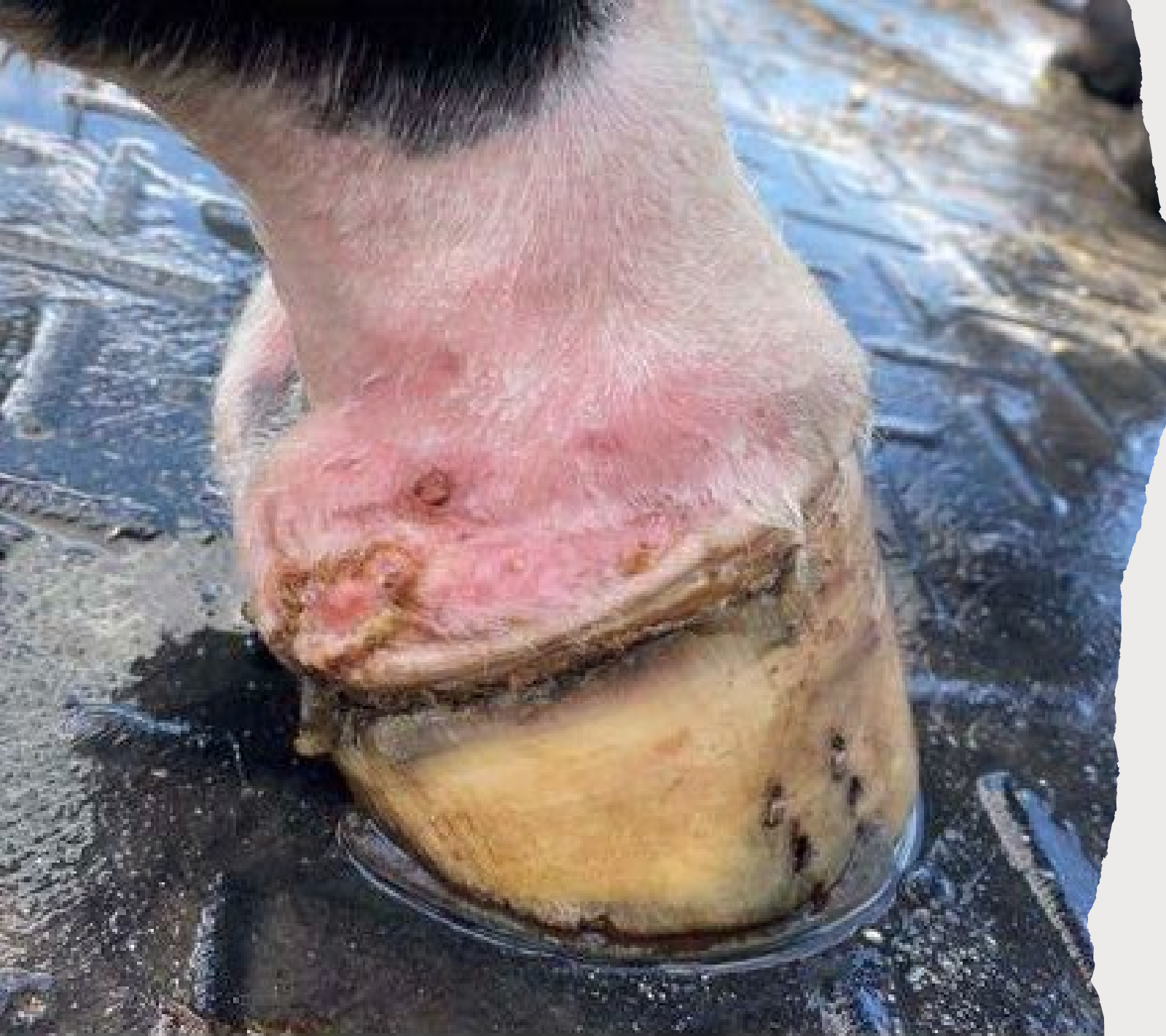

May 4th

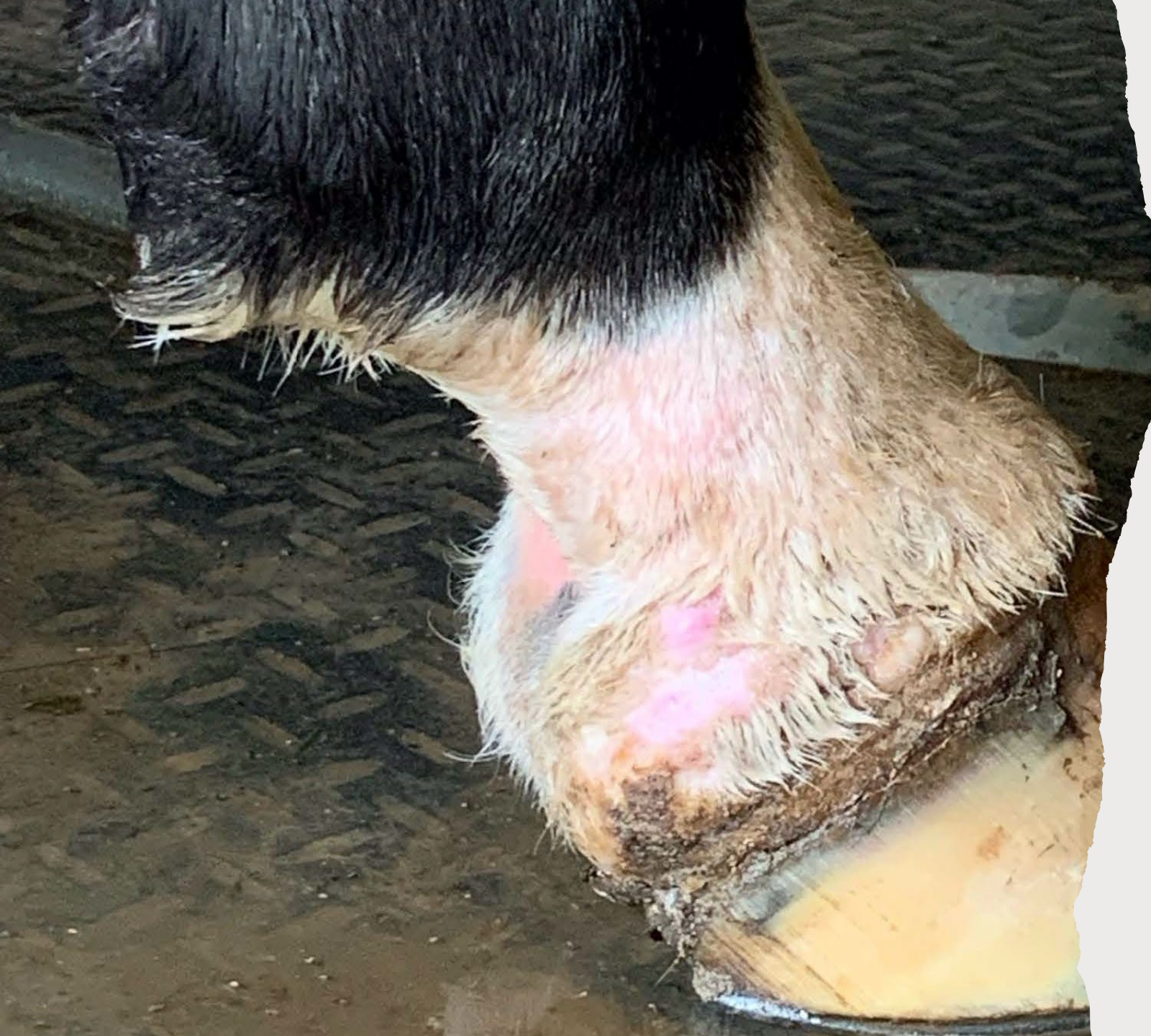

Post treatments  
on May 4<sup>th</sup>  
Tissue pink from  
light therapy





May 7<sup>th</sup>, 3 days  
later



May 25th



Dr Chris Newton  
Rood and Riddle



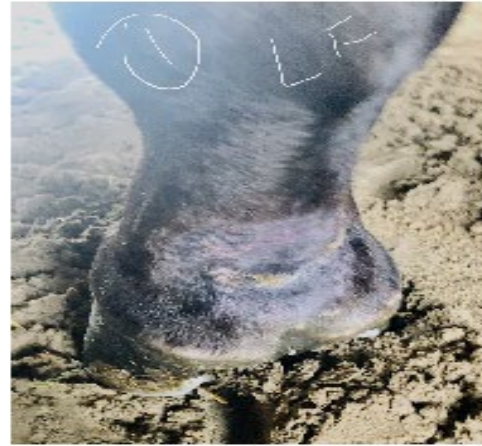## PHOVIA CASE 5

- 3 year old Thoroughbred
- History- chronic cracked heels, inflamed, painful
- Large horizontal lesions along pasterns- 2.5 inches
- Bilateral cracked heels

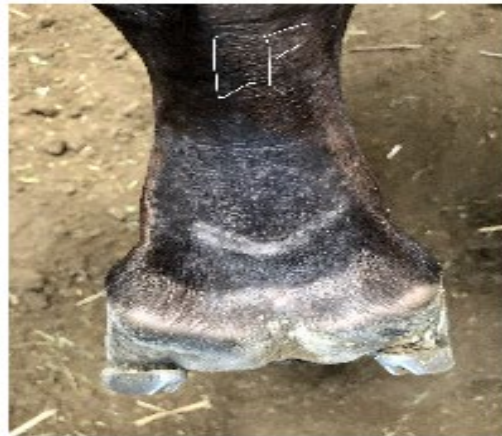
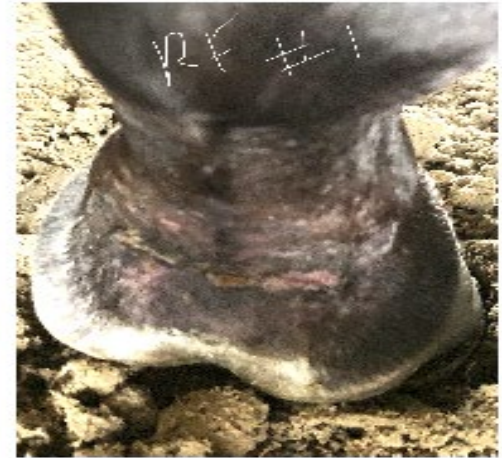


**Canoodling Santa Anita**



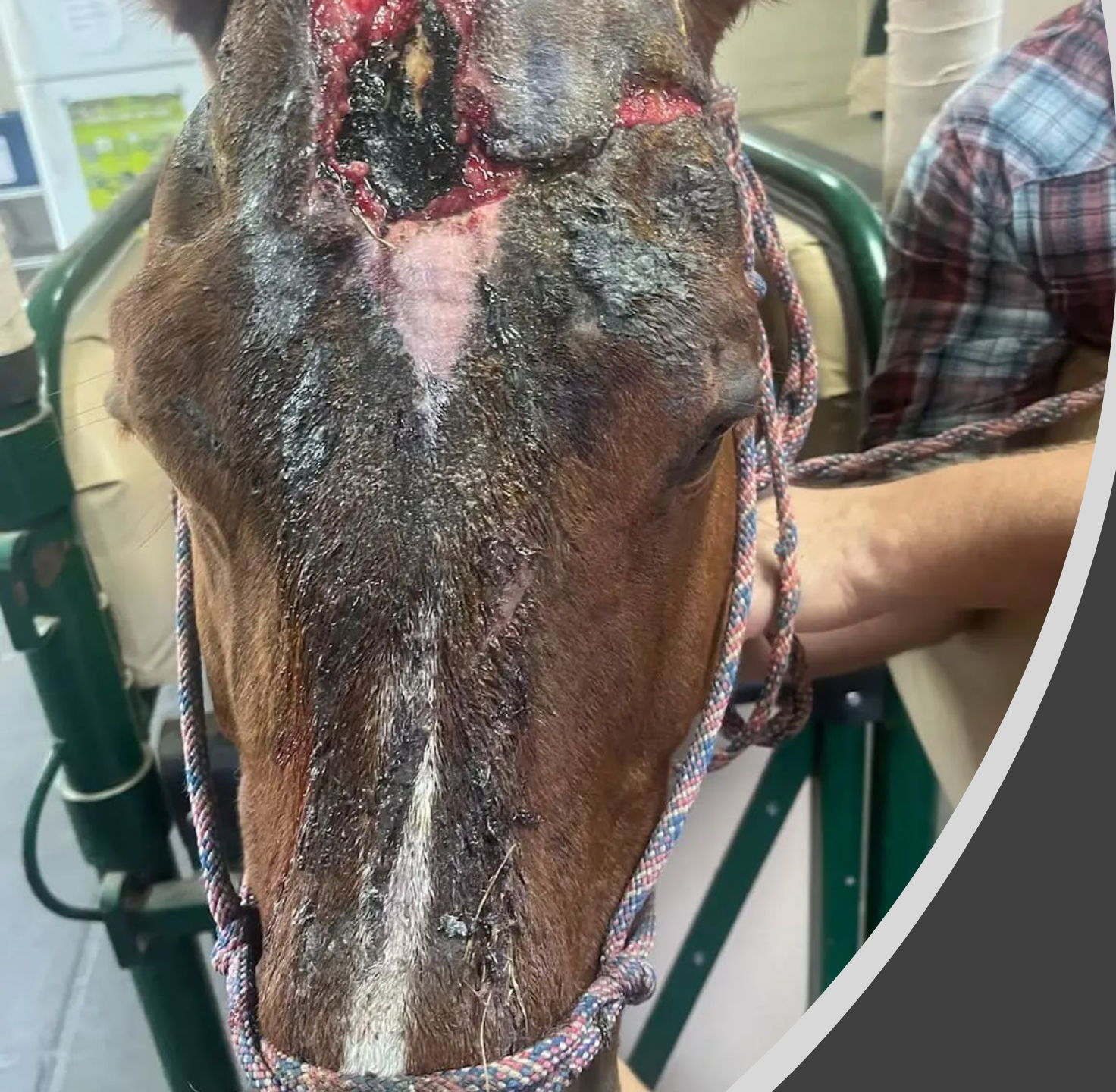**Before  
Phovia  
May 3**



**After  
Phovia  
May 11**





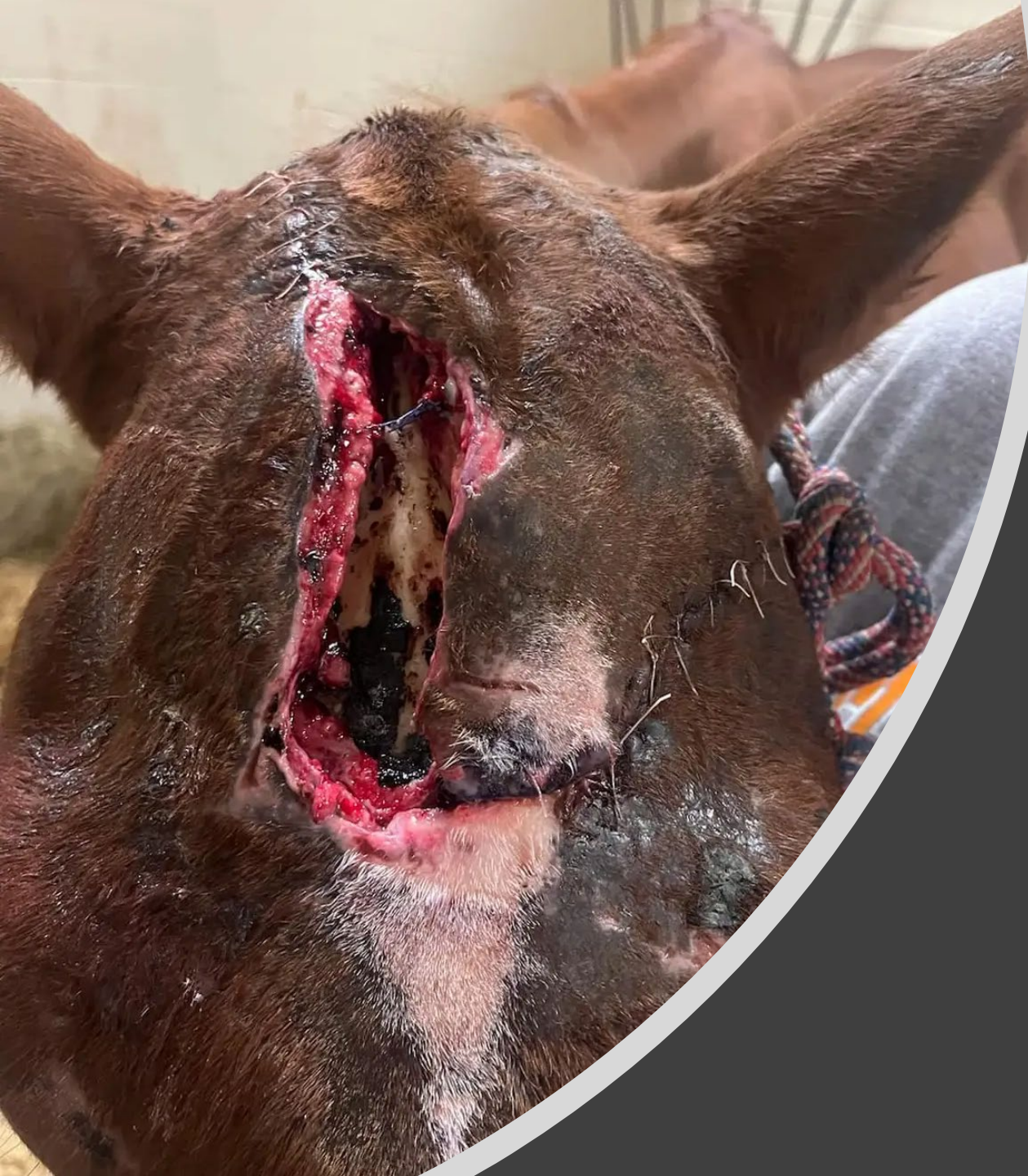

# Equine Injury on Presentation

Started on Equisul-STD, Phenylbutazone, Excede,  
And hypertonic saline bandage

COUNTRYSIDE  
VETERINARY SERVICES

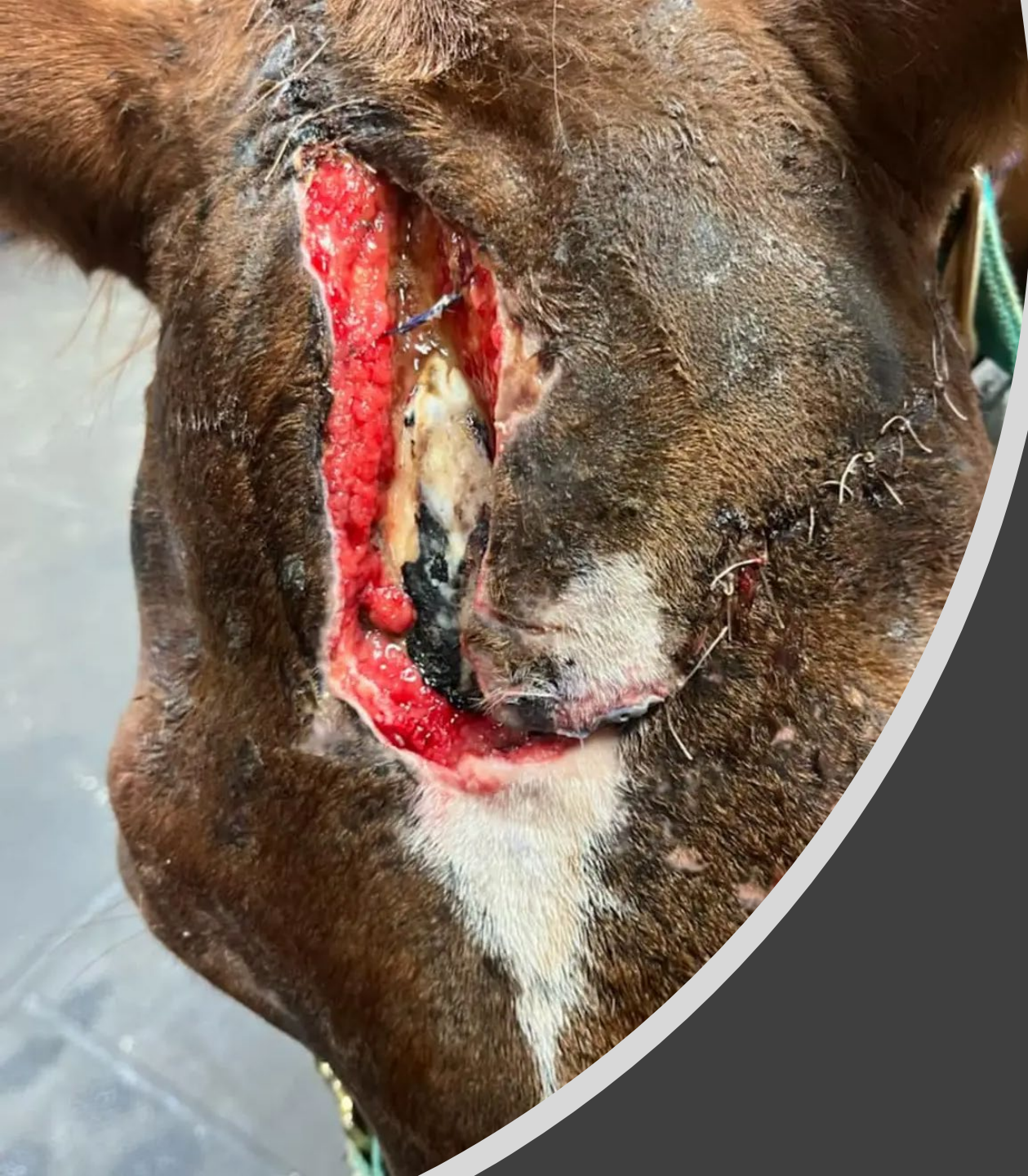



# Equine Injury After Debridement and Suturing

COUNTRYSIDE VETERINARY  
SERVICES





# Phovia Application #1 Equine Injury October 12, 2022

COUNTRYSIDE VETERINARY  
SERVICES

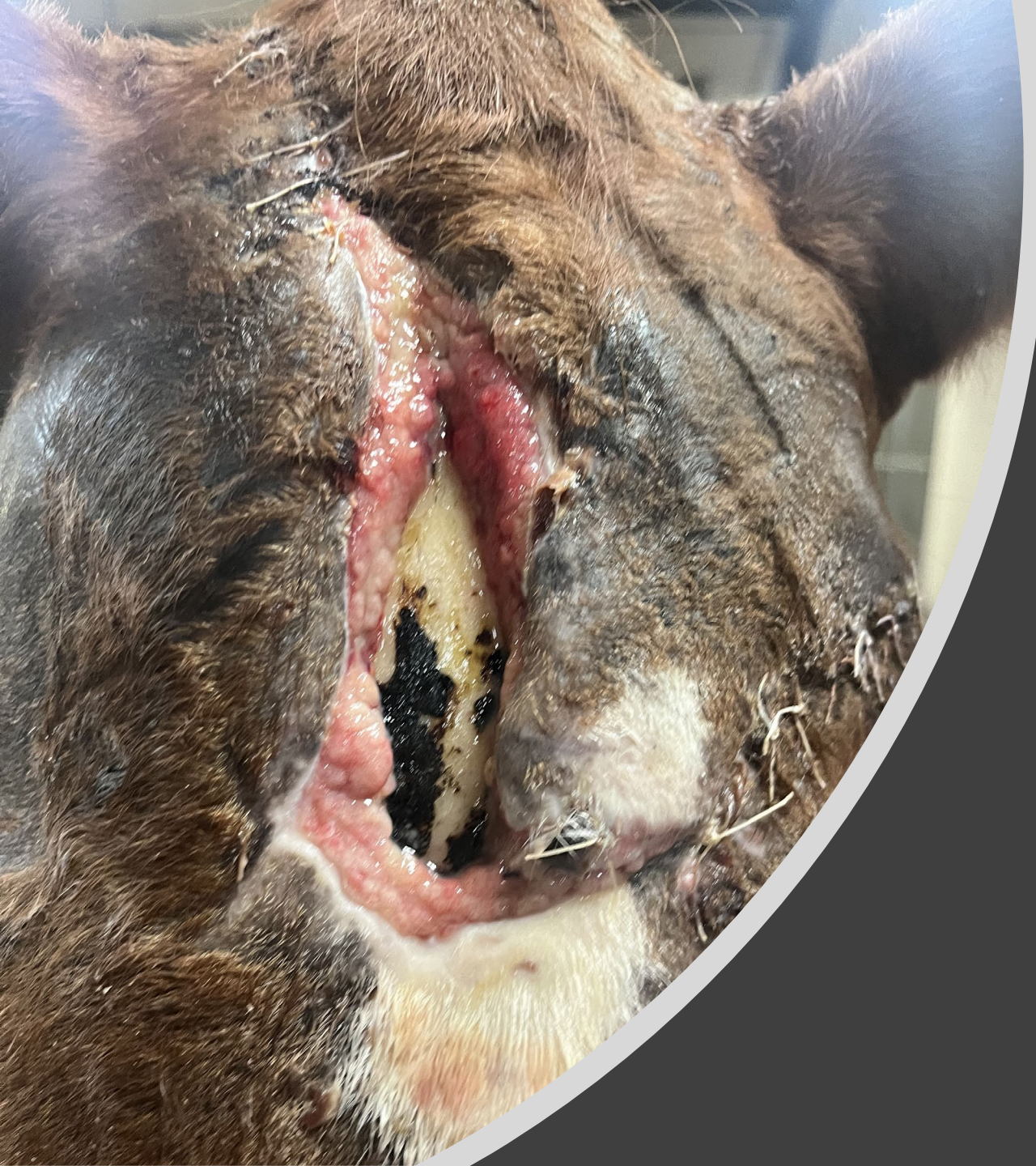



# Phovia Application #1 Equine Injury October 12, 2022

COUNTRYSIDE VETERINARY  
SERVICES





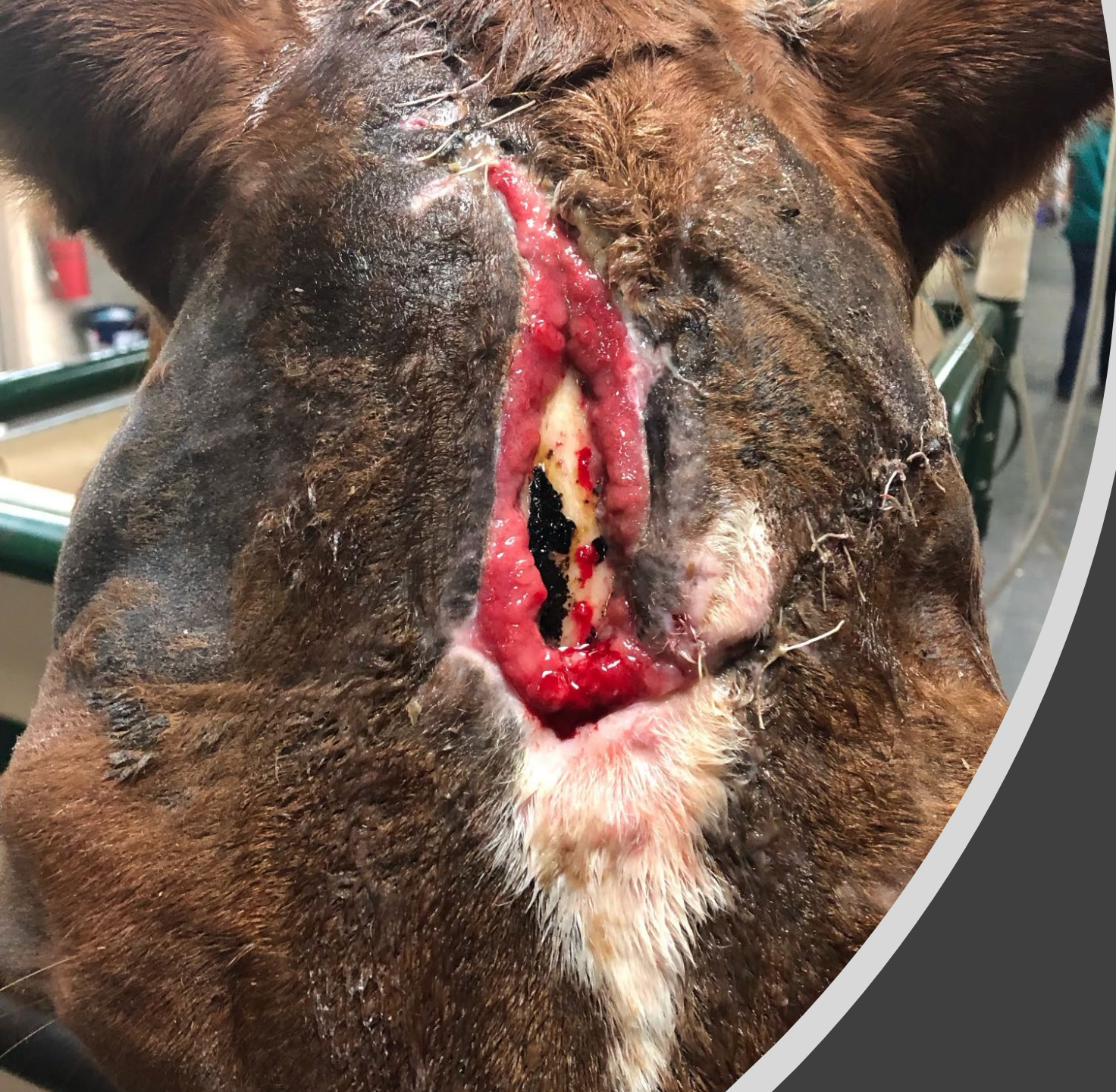# Phovia Application #2

## Equine Injury

### October 19, 2022

COUNTRYSIDE VETERINARY  
SERVICES

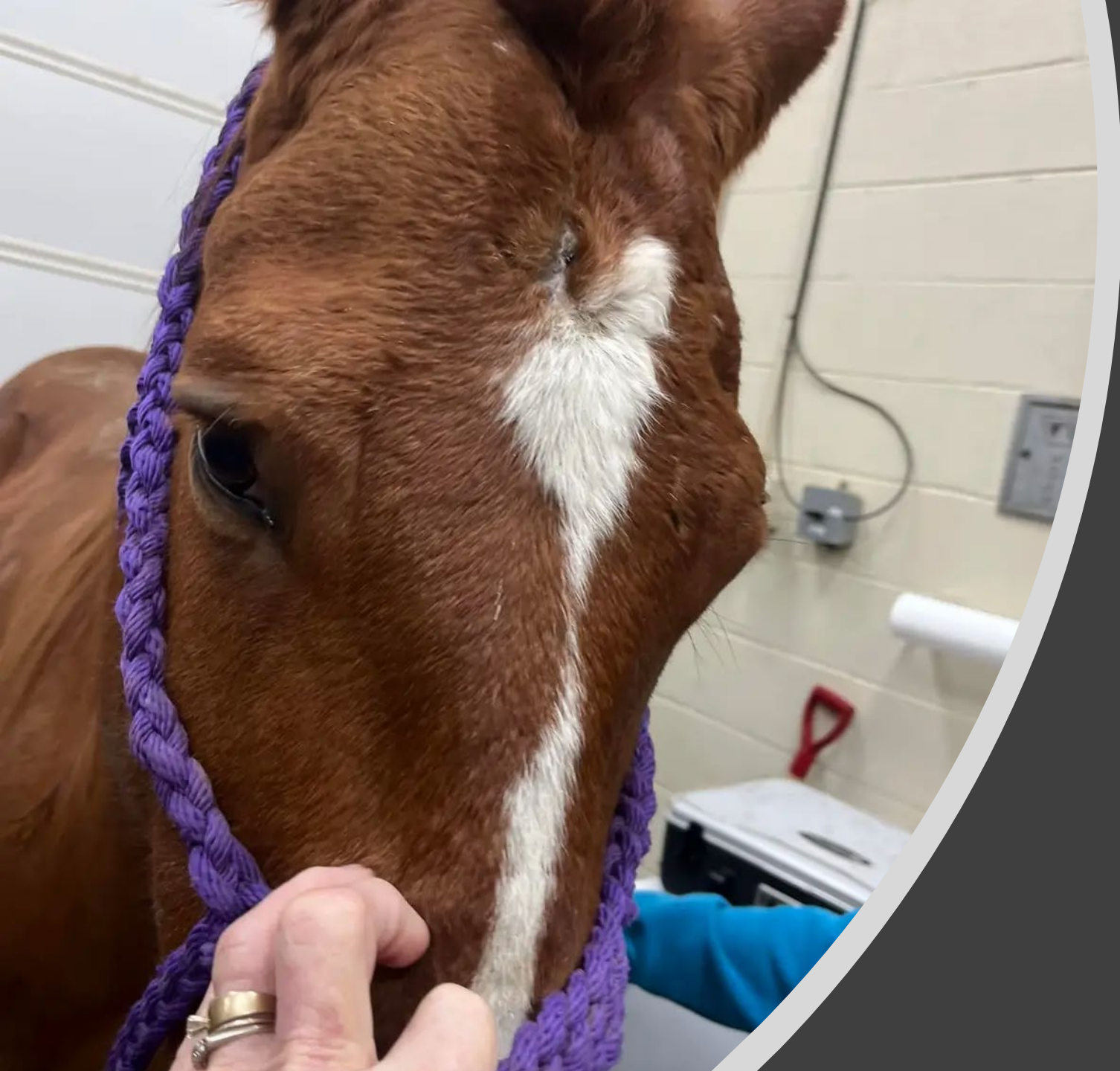



Phovia  
Application #3  
Equine Injury  
October 25, 2022

COUNTRYSIDE  
VETERINARY SERVICES





Patient 5 weeks  
after Phovia #3  
Last Week of  
November 2022

COUNTRYSIDE  
VETERINARY SERVICES